

Ocular Implications of Mpox

Steven Yeh, MD, FASRS

Professor and Stanley Truhlsen Jr. Chair in Ophthalmology

Global Center for Health Security

Truhlsen Eye Institute, Univ. of Nebraska Medical Center

Adjunct Professor, Emory University School of Medicine

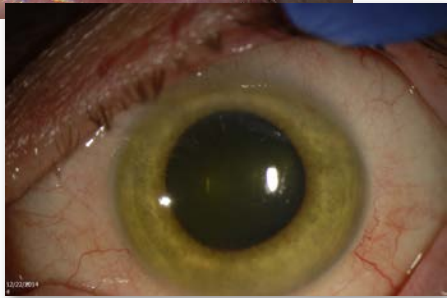
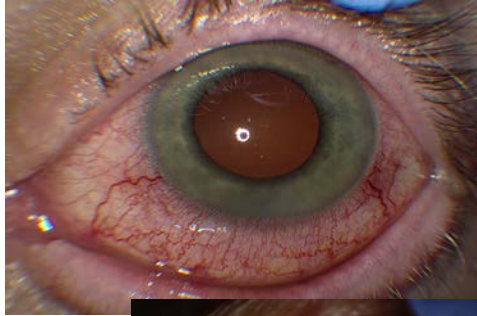
Jean-Claude Mwanza, MD, PhD, MPH

Professor of Ophthalmology

University of North Carolina at Chapel Hill

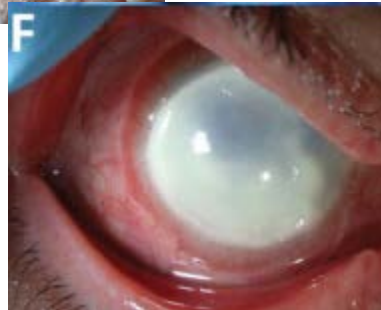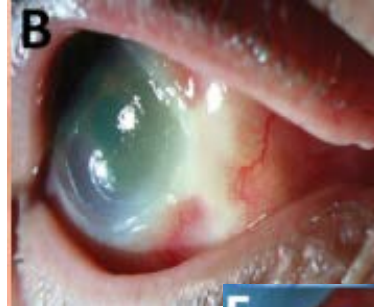
Dept of Ophthalmology, University of Kinshasa

The Eye as a Window to Emerging Infectious Diseases



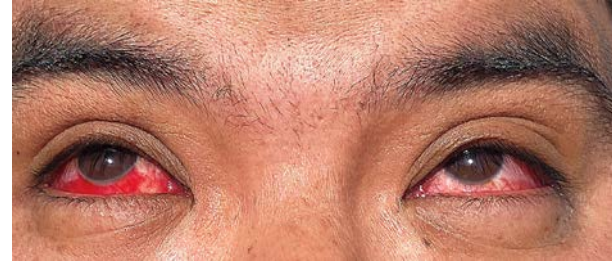Varkey et al *NEJM* 2015
Shantha et al *Ophthalmol* 2016

Ebola

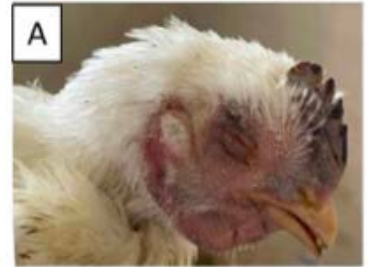

Nguyen, Seitzman, *Emerg Infect Dis* 2023

Mpox



Uyeki et al *NEJM* 2024

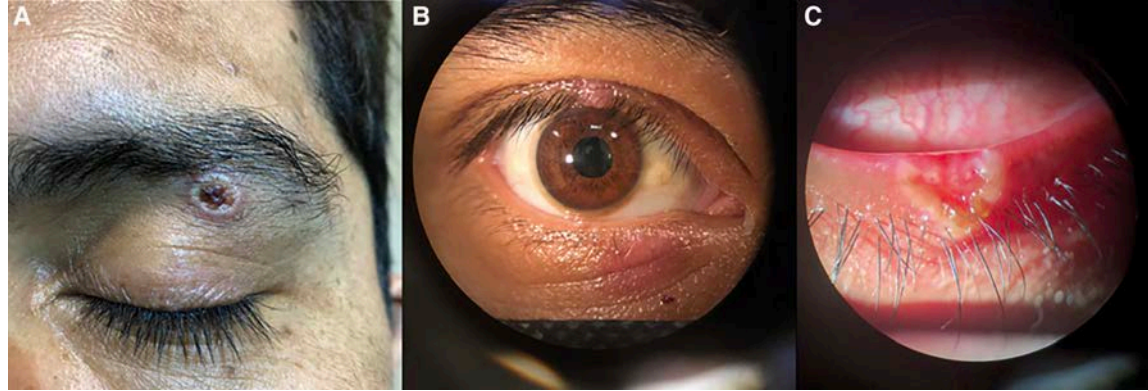


Landmann 2021

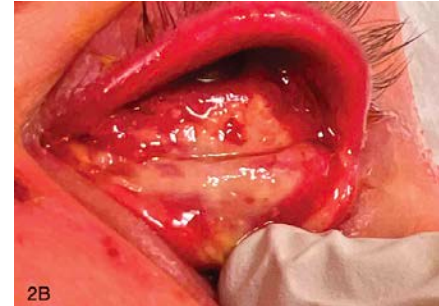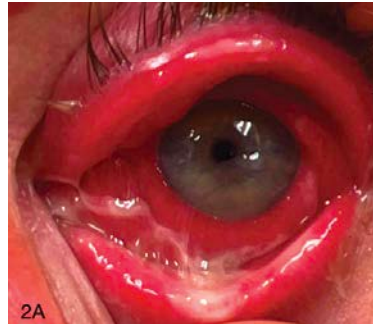*Highly Pathogenic
Avian Influenza*

Ophthalmic Implications of Mpox

- Clinical Features
 - Periocular, umbilicated lesions
 - Blepharitis
 - Conjunctivitis
 - Keratitis (Epithelial and stromal)
 - Uveitis, Hypopyon

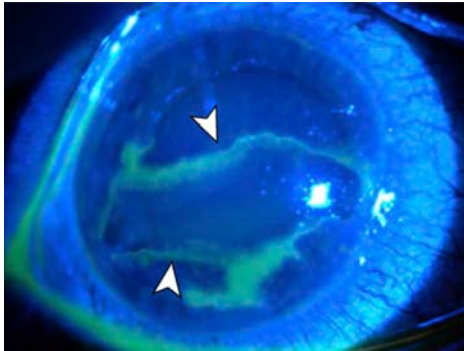
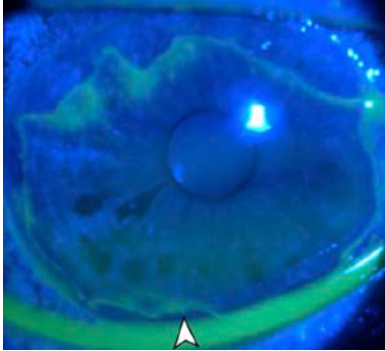


Rodriguez et al *J Infect Dis* 2024



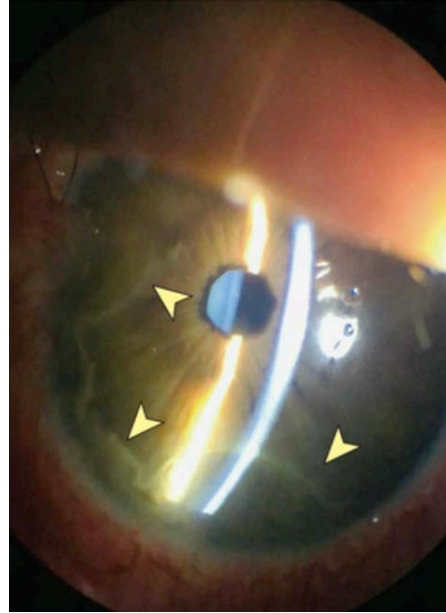
Uner et al *Cornea* 2023

Spectrum of Ocular Findings



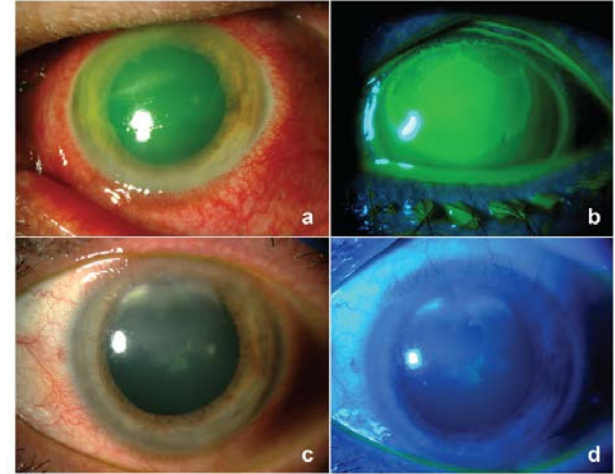
Progression of epithelial keratitis

Doan et al *JAMA Ophthalmol* 2023



Superficial peripheral keratitis

Finamor et al *JAMA Ophthalmol* 2022

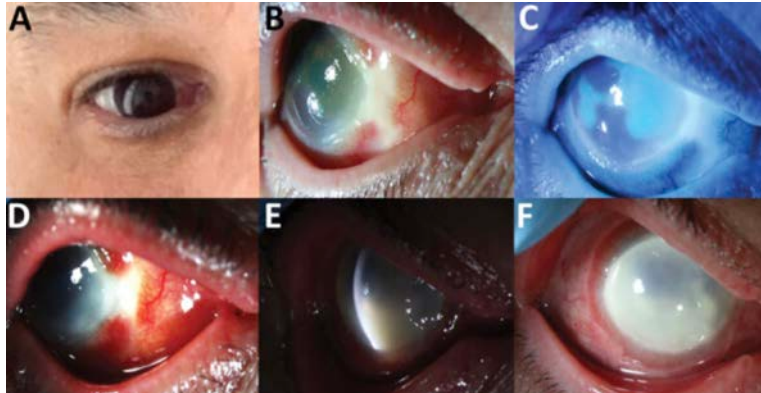


Corneal ulceration before and after treatment

Lamas-Francis et al *Ocul Imm Inflamm* 2024

Diagnostics and Molecular Detection

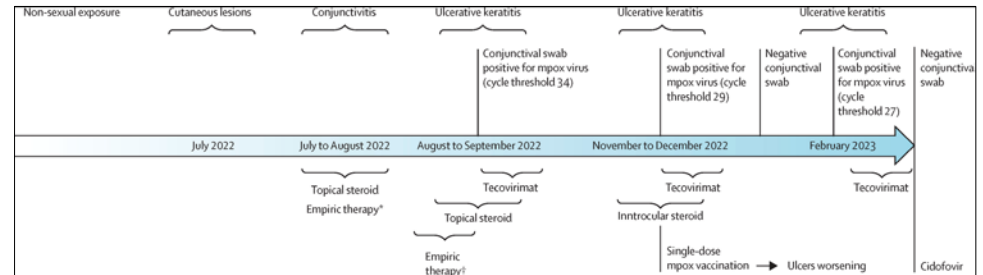
Isolated Ocular Mpox without Skin Lesions, United States



- HIV-negative patient with scleritis, keratitis, and uveitis
- Mpox virus confirmed in sclera and cornea by PCR
- Deep sequencing showed Mpox RNA in aqueous humor

Nguyen et al *Emerg Infect Dis* 2023

Persistent ocular mpox infection in an immunocompetent individual



- Persistent mpox ocular involvement for 8 months
- Symptoms improved with tecovirimat and topical corticosteroid but recurred with withdrawal
- Sx and infection resolved with tecovirimat and IV cidofovir

Raccagni et al *Lancet Infect Dis* 2023

Management Options and Preventive Measures

Systemic Treatment

Tecovirimat

Cidofovir

Brincidofovir

Vaccinia immunoglobulin IV (VIGIV)

Topical Therapies

Trifluridine 1%

Topical antibiotics (To prevent bacterial superinfection)

Ophthalmic lubrication

Kaufman et al. *JAMA*
Ophthalmol. 2023;141(1):78-83
Cash-Goldwasser et al. *MMWR*; 71:
1343-1347.

Preventive Measures

Patient and Family

- Frequent handwashing, hand hygiene
- Avoidance of eye rubbing

Health Care Provider / Ophthalmologist

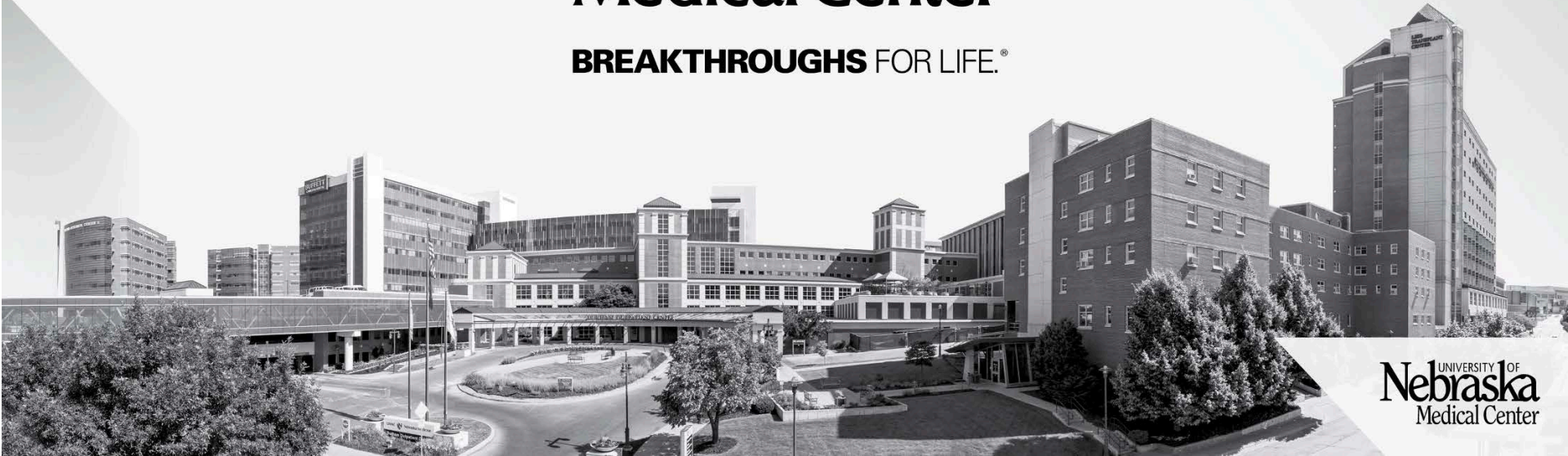
- IPC precautions and equipment disinfection protocols recommended (i.e., slit lamp biomicroscope, fundus exam)
- Source control (i.e., medical mask for patient)
- PPE: Gown, gloves, eye protection for front and sides of face, N95 respirator

www.cdc.gov



University of Nebraska Medical CenterSM

BREAKTHROUGHS FOR LIFE.[®]



UNIVERSITY OF
Nebraska
Medical Center